

Inflammatory Neuropathy Cause and Treatment (INCAT) disability scale

The INCAT disability scale assesses the functional ability of the arms and legs in patients with CIDP. Overall disability is measured by the arm disability score plus the leg disability score, which equals the overall score.¹

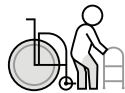(10=maximum disability; 0=no signs of disability)¹

INCAT: leg disability score¹



5

Restricted to wheelchair, unable to stand and walk a few steps with help



4

Usually uses wheelchair to travel outdoors, but able to stand and walk a few steps with help



3

Usually uses bilateral support (sticks, crutches, frame, 2 arms) to walk outdoors



2

Usually uses unilateral support (a stick, single crutch, or 1 arm) to walk outdoors



1

Walking affected, but walks independently outdoors



0

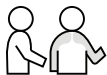Walking not affected

INCAT: arm disability score¹



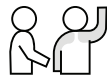
5

Inability to use either arm for any purposeful movement



4

Symptoms, in 1 arm or both arms, preventing 3 or all of the following functions: doing all zippers and buttons, washing or brushing hair, using a knife and fork together, handling small coins. Some purposeful movements still possible



3

Symptoms, in 1 arm or both arms, preventing 1 or 2 of the previously mentioned functions



2

Symptoms, in 1 arm or both arms, affecting but not preventing any of the previously mentioned functions



1

Symptoms, in 1 arm or both arms, not affecting the ability to perform any of the functions listed



0

No upper limb problems

CIDP=chronic inflammatory demyelinating polyneuropathy.

Reference: 1. Hughes R et al. *Ann Neurol.* 2001;50(2):195-201. doi:10.1002/ana.1088

For US audiences only.

© 2025 argenx US-CORP-24-00019 V2 04/2025.

INCAT © 2001 Wiley-Liss, Inc.

Hughes R, Bensa S, Willison H, Van den Bergh P, Comi G, Illa I, Nobile-Orazio E, van Doorn P, Dalakas M, Bojar M, Swan A; Inflammatory Neuropathy Cause and Treatment (INCAT) Group. Randomized controlled trial of intravenous immunoglobulin versus oral prednisolone in chronic inflammatory demyelinating polyradiculoneuropathy. *Ann Neurol.* 2001 Aug;50(2):195-201.